

Joint Program in Nuclear Medicine

Reflex Sympathetic Dystrophy Syndrome

John A. Moriarty, MD
David E. Drum, MD, PhD

May 1990

Presentation

A 58 year-old white male was referred for evaluation of right foot and ankle pain of four months duration associated with swelling. There was no history of trauma, surgery or infection. He had been placed in a plaster cast for several weeks for pain of unclear etiology. Erythrocyte sedimentation rate was 29. Alkaline phosphatase was normal.

Imaging Findings

The bone scintigram showed diffusely increased deposition of Tc-99m MDP in the ankle, subtalar, tarsal and metatarso-phalangeal joints of the right foot. Slightly increased radiotracer was deposited in the region of the tarso-matatarsal joints of the left foot. An X-ray of the right foot showed peri-articular osteopenia. A diagnosis of reflex sympathetic dystrophy syndrome was made. The patient markedly improved on conservative treatment.

Discussion

Clinical:

RSDS has been considered as a distinct entity since the description by Mitchell (1). He used the term, 'Causalgia'. However, this was later recognized as part of a spectrum of conditions which have in common non-specific findings such as hyperalgesia, vasomotor abnormalities and variable skin changes. Edema is often present. DeTakats, Steinbrocker and Evans unified this miscellany under the title, 'Reflex Sympathetic Dystrophy Syndrome'. This is appropriate because of the apparent involvement of the autonomic nervous system. The most frequently observed varieties are Sudeck's atrophy and the Shoulder Hand Syndrome. Kozin (2) demonstrated that the syndrome is often bilateral and provided a clinical classifications. Severity ranges from minor, which includes Sudeck's atrophy, to major causalgia, which is usually associated with major nerve damage. In such cases pain usually corresponds to the cutaneous distribution of the injured nerve. There is a slight female preponderance.

Reflex sympathetic dystrophy syndrome (RSDS) often follows trauma or surgery. In 506 patients selected by Sleinert from a large post-operative series, 25%% followed operations for crush injuries, 25%% followed elective operations in the upper extremities, e.g., carpal tunnel release, palmar fasciotomies, and 50%% followed sprains, contusions and other operations. Symptoms begin immediately after injury in 30%% of patients; in the remainder they usually start during the first week.

The Should Hand Syndrome is a variant of RSDS often related to myocardial infarction, cervical disk

herniation and degenerative disease of the cervical spine.

Other correlates of RSDS include sepsis, systemic viral infections and spinal cord concussion. RSDS may occur in many hospitalized stroke patients. Kozin reports a figure of 14%% and Tepperman 25%%. Rarely RSDS may be associated with underlying carcinoma (bladder, lung and esophagus), herpes zoster and isoniazid therapy.

Local sympathetic blockade is used in therapy and diagnosis.

Radiological Evaluation:

Patchy osteoporosis is the primary roentgenologic manifestation of RSDS. This non-specific finding is usually periarticular and associated with soft tissue swelling. Erosions of the subchondral bone may also be found.

There has been a great deal of controversy about the precise findings on scintigraphy. Although in adults increased activity is usually observed in the affected regions, Matter studied 32 patients and concluded that the pattern of decreased activity described in children is occasionally encountered in adults. This variability may be related to the interval between onset of symptoms and imaging. Demangeat (3) studied 181 patients with RSDS of the hand providing quantitative measurements of blood flow (BF), blood pool (BP) and delayed images (DI). He divided the studies into three stages based on interval from onset of symptoms.

Stage	Weeks	BF	BP	DI
1	0-20	INC	INC	INC
2	20-60	N	INC	INC
3	60-100	DEC	N	N

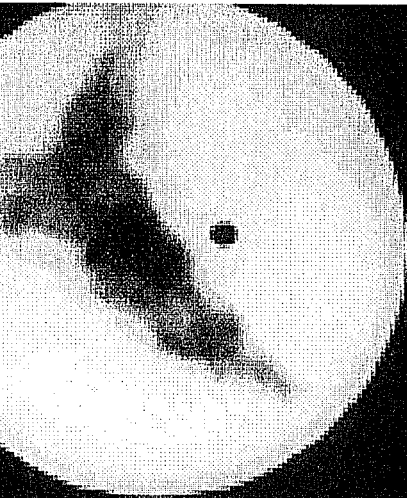
INC=increased, DEC=decreased, N=normal

The reduced flow in advanced RSDS may be due in part to amyotrophia caused by disuse.

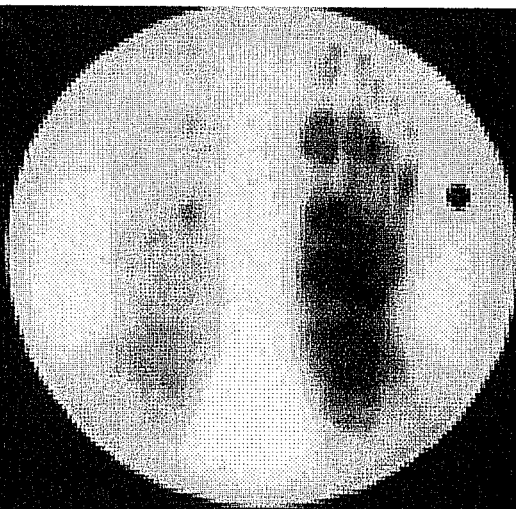
Intenzo (7) recently found that 28%% of 32 patients with RSDS of the lower extremities had normal scans, 59%% showed increased and 13%% showed decreased activity; overall sensitivity was 72%%. Values for the sensitivity and specificity of the one scan for RSDS vary amongst authors, however. Werner (6) reported a sensitivity of 50%% and a specificity of 92%% based on the delayed image. When blood flow and blood pool images were considered these values were not altered. MacKinnon and Holder (4) reported significantly higher values: sensitivity=96%%; specificity=98%%.

Goldsmith (5) evaluated the three phase bone scan in children and the lower extremity was affected much more frequently than in adults (12/15). Only one radiograph showed mild diffuse osteopenia, but the bone scan showed decreased uptake in 12/15. Increased uptake was the pattern in two patients. Blood flow and blood pool images did not increase the sensitivity.

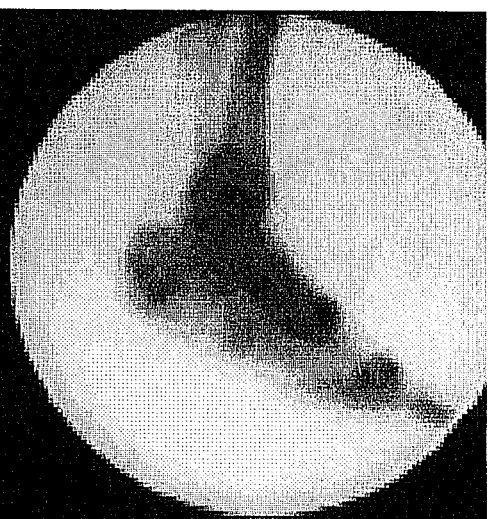
Scintigraphy appears to be a useful guide to prognosis. 90%% of patients with positive scintigrams experienced a favorable response to steroids as opposed to 34%% of those with negative scintigrams (2).



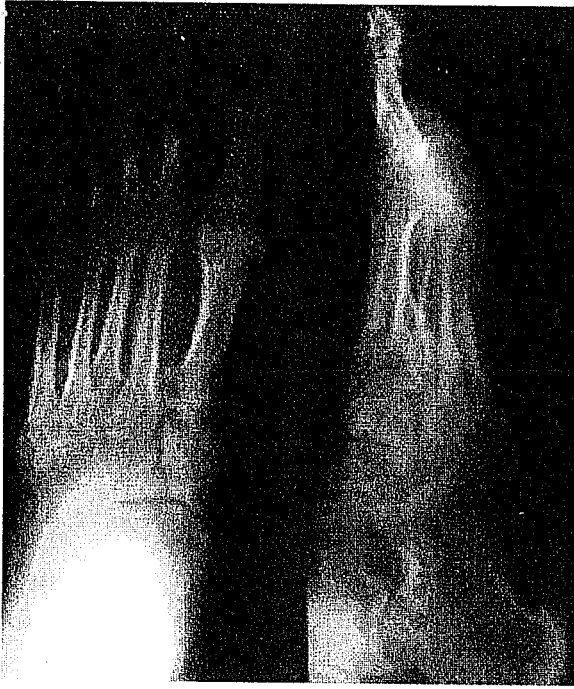Rt. Foot



Plantar



Lt. Foot



Conclusions:

- Changes on the roentgenogram are not specific.
- Findings on the bone scan depend to a great extent on the stage of the disease.
- Blood flow and blood pool images did not increase the sensitivity. The static delayed image appears most useful.

References

- 1) Mitchell SN, et al. Gunshot wounds and other injuries of nerves. Lippincott, Philadelphia, 1964.
- 2) Kozin F, et al. RSDS. AJM 1976; 60:321 and 1981; 70:23-30.
- 3) Demangeant JL, et al. Three-phase bone scanning in RSDS of the hand. JNM 1988; 29:26-31.
- 4) MacKinnon SE, Holder LE. The use of three-phase bone scanning in the diagnosis of RSDS. J Hand Surg 1984; 9A:556-563.
- 5) Goldsmith DP, et al. Nuclear imaging and clinical features of childhood RSDS: comparison with adults. Arthr Rheum 1989; 32:480.
- 6) Werner R, et al. Factors affecting the sensitivity and specificity of the three-phase bone scan in the diagnosis of RSDS in the upper extremity.
- 7) Intenzo C, et al. Scintigraphic patterns of RSDS of the lower extremities. Clin Nucl Med 1989; 14(9):657-661.

Comments on this case

Click [here](#) to go to Joint Program in Nuclear Medicine home page and Copyright notice.

J. Anthony Parker, MD PhD, Tony_Parker@bih.harvard.edu